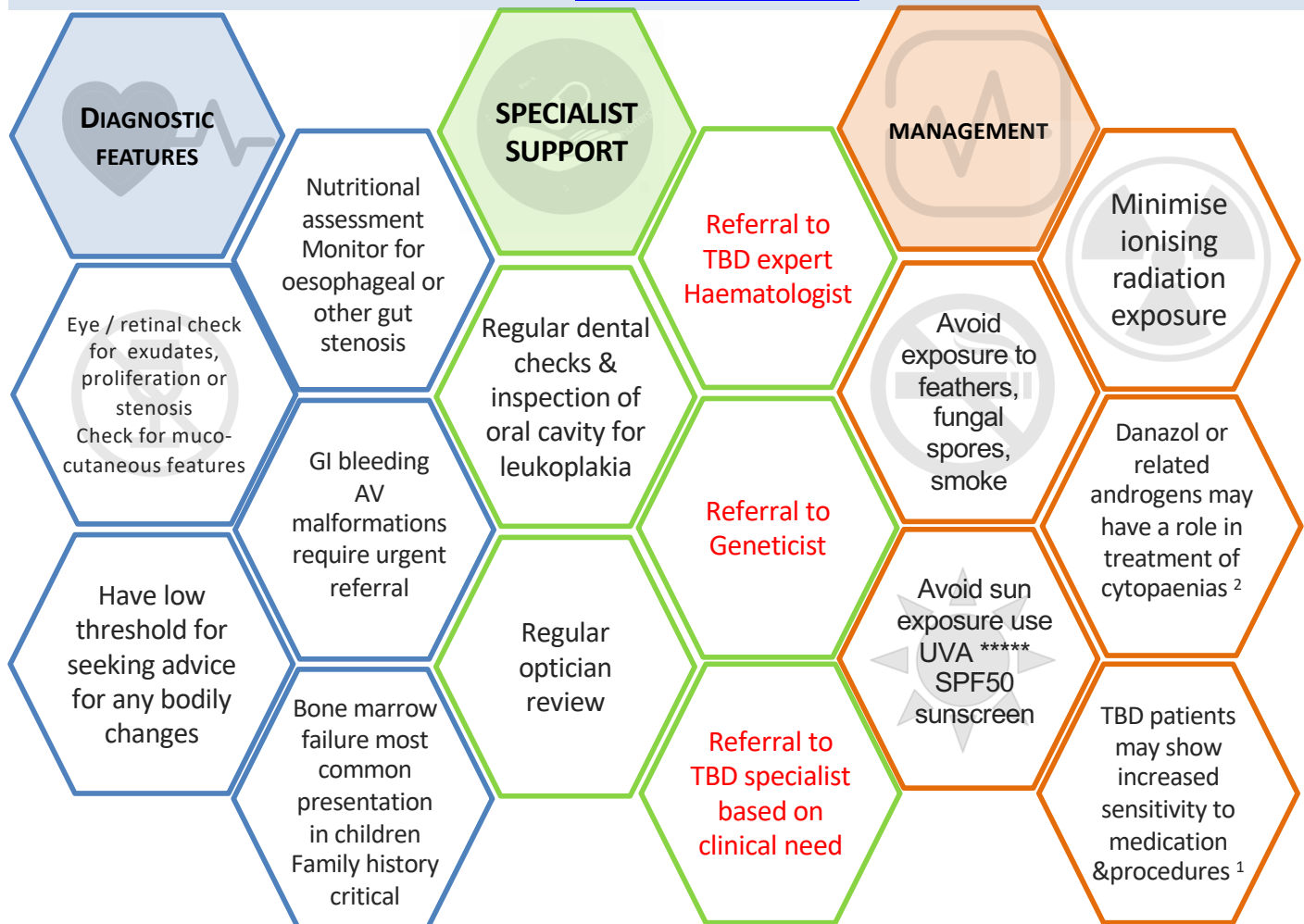


General Practice considerations: TBDs in children

Alterations in telomere associated genes result in short telomeres and impaired cell replication. Alterations in fourteen identified genes, together with environmental factors, have been shown to lead to premature cell death and chromosome instability. Dyskeratosis congenita (DC) and Hoyeraal-Hreidarsson (HH) syndrome present with the most severe multi-organ clinical manifestations but mutations in any of the telomere genes can show variable penetrance and phenotype with disease onset possible in childhood or later life.

Savage SA. Dyskeratosis congenita 2009 (updated 2019 Nov 21) in Adam MP, Ardinger HH, Pagon RA *et al.*, Eds. Gene Reviews® [internet] Seattle (WA): University of Washington Seattle; 1993-2019. Bookshelf URL <https://ncbi.nlm.nih.gov/books/>

Marena R. Niewisch & Sharon A. Savage (2019) An update on the biology and management of dyskeratosis congenita and related telomere biology disorders, Expert Review of Hematology, 12:12, 1037-1052, DOI: [10.1080/17474086.2019.1662720](https://doi.org/10.1080/17474086.2019.1662720)



Specialist involvement will vary between patients, however recommended minimum annual surveillance should include

- Complete blood count
- Liver function assessment including bloods and fibro/fat scan
- Respiratory spirometry and gas transfer
- Dental (six monthly) + ENT review
- Optician
- Nutritional status review
- Annual flu vaccine for patient and household members
- Screen for depression and anxiety

¹Including methotrexate, long term nitrofurantoin, bleomycin, busulphan, amiodarone and as per www.pneumotox.org

²Androgens/danazol are assumed acceptable as perceived benefit probably outweighs risk. See Townsley *et al* N Engl J Med 2016;374:1922-31. DOI: 10.1056/NEJMoa1515319

We value your feedback. Please contact us.



ADVOCACY



EDUCATION



SUPPORT

This information is based on medical literature. Please see your doctor if you have concerns about TBD



Telomere Biology Disorders (TBD) are genetic disorders that affect cell production and replication in multiple organ systems. Dyskeratosis Congenita (DC) is a severe TBD that commonly presents in early childhood with a clinical triad of nail dysplasia, oral leukoplakia, and abnormal skin pigmentation associated with bone marrow failure. Clinical features can include pulmonary fibrosis; emphysema; cryptogenic liver cirrhosis; lacrimal duct, oesophageal, and urethral stenosis, premature greying of hair, avascular necrosis of hips and shoulders, periodontal disease and an increased predisposition to epithelial and hematologic malignancies. Classical DC, usually evident in childhood, is characterized by extremely short telomeres and a severe clinical phenotype but different gene mutations in an array of telomere maintenance genes can produce variable phenotypes differing in severity, in children or adults. Mutations in *DKC1*, *TERC*, *TERT*, *CTC1*, *NHP2*, *NAF1*, *NOP10*, *WRAP53*, *TINF2*, *RTEL1*, *PARN*, *ACD*, *STN1* and *ZCCHC8* have been identified in patients with the above spectrum of clinical manifestations. A family history should be an index of suspicion. TBD symptoms can appear at any age with adult-onset bone marrow failure difficult to distinguish from idiopathic aplastic anemia. The effects of TBD can be variable in severity and clinical prognosis is difficult to predict. Multi-system complications can emerge at any time during a patient's life necessitating lifelong follow-up and monitoring. The heterogenous course of possible clinical development make recommendations for frequency of monitoring difficult but blood tests, bone marrow examinations, pulmonary function tests etc. on an annual basis are advisable. Liaison with a specialist centre providing multi-disciplinary disciplinary monitoring, treatment and care is vital.

Savage SA. Dyskeratosis congenita 2009 (updated 2019 Nov 21) in Adam MP, Ardinger HH, Pagon RA *et al.*, Eds. Gene Reviews® [internet] Seattle (WA): University of Washington Seattle; 1993-1019. Bookshelf URL <https://ncbi.nlm.nih.gov/books/>
Niewisch MR & Savage SA (2019) An update on the biology and management of dyskeratosis congenita and related telomere biology disorders, Expert Review of Hematology, 12:12, 1037-1052, DOI: [10.1080/17474086.2019.1662720](https://doi.org/10.1080/17474086.2019.1662720)

Medical Management of Bone Marrow Failure

Significant peripheral cytopenia should be managed with supportive therapy ie: blood and platelet transfusions. Anabolic steroids or androgens may be used to treat bone marrow failure and preserve telomere length.

NB: No androgen or steroid therapy is licensed for treatment of Telomere Biology Disorders. Prescriptions are likely to be personalised by a specialist haematologist.

Khincha PP *et al.* Response to Androgen Therapy in Patients with Dyskeratosis Congenita' Br J Haematol. 2014 May; 165(3): 349–357.

Chapter 11 Dyskeratosis congenita by I. Dokal in K.E. Sullivan and E.R. Stiehm (Eds): In Stiehm's Immune Deficiencies. DOI: <http://dx.doi.org/10.1016/B978-0-12-405546-9.00011-X>

Islam A *et al.* Haematological recovery in dyskeratosis congenita patients treated with danazol. British Journal of Haematology, 2013, 162, 842–862.

Townsley DM *et al.* Danazol treatment for telomeres diseases. N Engl J Med 2016;374:1922-31.

Khincha PP *et al.* Similar telomere attrition rates in androgen-treated and untreated patients with dyskeratosis congenita. Blood Advances 2018;Vol 2: 11.

Chapter 7 Medical Management of Bone Marrow Failure in Dyskeratosis Congenita. Neelam Giri, MD, Neal S. Young, MD. In Savage, S. A. & Cook, E. F. Eds. (2015) DC & Telomere Biology Disorders: Diagnosis & Management Guidelines. TeamTelomere.org

Stem Cell Transplantation and conditioning regimens

At the present time, allogeneic hematopoietic stem cell transplantation (HSCT) is the only curative option for progressive marrow failure, myelodysplastic syndrome, or leukaemia related to dyskeratosis congenita and telomere biology disorders. Underlying chromosomal instability and sensitivity to chemotherapy and radiation preclude traditional conditioning regimens. Non-myeloablative conditioning regimens designed for TBD patients are recommended prior to HSCT.

Dietz AC *et al.* Disease-specific hematopoietic cell transplantation: nonmyeloablative conditioning regimen for dyskeratosis congenita. Bone Marrow Transplantation (2011) 46, 98–104.

Nelson AS *et al.* A Reduced-Intensity Conditioning Regimen for Patients with Dyskeratosis Congenita Undergoing Hematopoietic Stem Cell Transplantation. Biol Blood Marrow Transplant. 2016 May 22(5): 884-888.

Pulmonary Fibrosis and Liver Cirrhosis

Pulmonary fibrosis and liver cirrhosis can be primary manifestations of Telomere Biology Disease. Consider an inherited telomeropathy in early onset cirrhosis / fibrosis. Lung or liver fibrosis plus a family history of bone marrow failure should raise suspicion. Pulmonary fibrosis may occur following HSCT.

Donati B and Valenti L. Review. Telomeres, NAFLD and Chronic Liver Disease. Int. J. Mol. Sci. 2016, 17, 383.

Giri N *et al.* Prognostic significance of pulmonary function tests in dyskeratosis congenita, a telomere biology disorder. ERJ Open Res 2019; 5: 00209- 2019 [<https://doi.org/10.1183/23120541.00209-2019>].

Dental and Oral Manifestations

A diagnosis of DC or other inherited Telomere Biology Disorder should be considered in young persons with oral leukoplakia. There is evidence of increased risk of oral cancers in Telomere Biology Disorders. Periodontal hygiene is critical in HSCT patients.

Atkinson JC *et al.* Oral and Dental Phenotype of Dyskeratosis Congenita. Oral Dis. 2008 July; 14(5): 419–427.

Fatehi KS *et al.* Squamous cell carcinoma of the tongue in a patient with Dyskeratosis congenita: a rare entity. Br. J. Oral and Maxillofacial Surgery: 57(2019) 79-81.

Cancer Risk

There is evidence of increased risk of cancers in Dyskeratosis congenita (DC) /Telomere Biology Disorders, especially head and neck, urogenital and epithelial cell cancers.

Alter BP *et al.* Cancer in the National Cancer Institute inherited bone marrow failure syndrome cohort after fifteen years of follow-up. Haematologica 2018 Volume 103(1):30-39.

Neurology / Psychiatric

Structural brain abnormalities and variants are common in TBDs, as are neurologic and psychiatric symptoms.

Bhala S *et al.* CNS manifestations in patients with telomere biology disorders. Neurol Genet Dec 2019, 5 (6) 370; DOI: 10.1212/NXG.0000000000000370